98 Dermal Hypertrophies

Salma Machan, Ana María Molina-Ruiz and Luis Requena

Chapter Contents

Hypertrophic Scars and Keloids 1730
Dupuytren Disease 1733
Cutis Verticis Gyrata 1735
Hyaline Fibromatosis Syndrome 1736
Elastic Tissue-Related Disorders 1738

This chapter will discuss disorders in which there are increased amounts of collagen within the skin, followed by those with increased elastin.

HYPERTROPHIC SCARS AND KELOIDS

Key features

- Conventional scars are preceded by injury, form within weeks, remain flat or minimally elevated, and are asymptomatic
- Hypertrophic scars are raised, firm, and confined to the wound margin. Sometimes they improve spontaneously and tend to have a good response to treatment
- Keloids extend beyond the wound margin and are delayed in onset. They seldom resolve spontaneously and response to treatment is often poor

Introduction

All wounds heal with some degree of scar formation, but the mechanisms that govern whether the result will be a fine thin scar, a prominent hypertrophic scar, or a tumor-like keloid remain unclear. The latter represent two forms of abnormal wound healing characterized by local fibroblast proliferation and excessive collagen production in response to cutaneous injury. However, their clinical and histopathologic features differ, as well as proposed pathogeneses.

Epidemiology

Hypertrophic scars develop more often than keloids, and keloids have a higher prevalence in individuals with more darkly pigmented skin including Africans, African-Americans, Hispanics, and Asians[1]. In these populations, an incidence ranging from 4%–16% has been reported[2]. Neither hypertrophic scars nor keloids have a sex predilection, and both entities occur most frequently in those 10 to 30 years of age[3]. Individuals in this age group are more often subjected to trauma and their rate of collagen synthesis is higher. Younger skin also possesses greater tension, as compared to older skin which has less elasticity and is more redundant[2].

Etiology

Proposed etiologic factors include: genetic predisposition; depth, type, and location of the skin injury or wound; degree of tension; local infection or inflammation; and hormonal influences[2,3]. Possible autosomal dominant inheritance with incomplete clinical penetrance and variable expression has been suggested[3]. A range of skin injuries can lead to abnormal scarring, from lacerations, burns, surgical excisions, and skin piercings to injections (vaccines, tattoo inks) and cutaneous inflammation (e.g. acne vulgaris, insect bites)[4]. Moreover, tension is constantly transmitted to the skin from the underlying cartilaginous and bony skeleton, and skin tension can be aggravated by loss of tissue, as occurs with surgical excisions[5]. In addition, hormonal influences have been proposed as an explanation for the appearance of keloids at or after puberty and their resolution following menopause, as well as reports of the onset or enlargement of keloids during pregnancy[2]. Lastly, spontaneous keloids may occur in the absence of any obvious trauma or inflammation, although there is the possibility of unrecognized skin disease (e.g. acne).

Future insights into etiology may come from the genetic disorders in which keloids are an associated feature, including Bethlem myopathy, Rubinstein–Taybi, Warburg–Cinotti and Goeminne syndromes, fronto-metaphyseal dysplasia, and other filamin A-related disorders (see Table 95.5)[6,7]. Patients with polyfibromatosis (see below) can also develop keloids.

Pathogenesis

The ability to heal wounds created by injuries, in particular trauma, offers an evolutionary advantage, with associated scarring being less of an issue. However, cutaneous scarring resulting from surgical procedures is viewed as an unwanted consequence. A regenerative response would be preferred, thereby conceivably providing a superior cosmetic result and avoiding the formation of hypertrophic scars and keloids[8]. Notably, in regenerative healing, there is an absence of inflammation in addition to a lack of scarring. In fetuses, cutaneous wounding during the first and second trimesters of gestation does not lead to scarring, and this is thought to reflect a healing process that is occurring via tissue regenerative pathways in a sterile environment and in the absence of inflammation[9].

Excess scar formation is thought to result from dysregulation during at least one of the three phases of wound healing – inflammatory, proliferative, and remodeling/maturation (see Fig. 141.2)[8–12]. Proinflammatory cytokines such as interleukin-6 (IL-6) and IL-8 have been associated with increased scar formation while the anti-inflammatory cytokine IL-10 can lead to a reduction in scar tissue[8]. Several additional factors have been shown to play a role in enhancing fibroblast-related scar formation, including transforming growth factor (TGF)-β, platelet-derived growth factor (PDGF), the transcription factor homeobox B13, and components of the Wnt signaling pathway[8]. Greater insights into regulation of crucial components of the remodeling phase, e.g. cessation of granulation tissue formation, will hopefully provide targets for preventative or therapeutic interventions for hypertrophic scarring.

Because keloid formation only occurs naturally in humans, the ability to use animal models is limited[9]. In studies utilizing biopsy specimens of keloids, collagen synthesis by fibroblasts is markedly increased as is the production of TGF-β, a key regulatory factor during the proliferative phase of wound healing. However, different TGF-β isoforms may play distinct and even competing roles in wound healing. Expression of TGF-β1 or TGF-β2 may lead to an increase in scarring, whereas expression of TGF-β3 has been associated with a reduction in scarring[13]. This has led to the introduction of therapies that specifically address these different forms of TGF-β (see Table 98.4).

Clinical Features

Distinguishing clinically between a hypertrophic scar and a keloid is usually straightforward, but sometimes it can be difficult if the lesion is small or of recent onset. The characteristic features of hypertrophic scars and keloids are outlined in Table 98.1. Both have a smooth surface, are firm to palpation, and may be pruritic or painful. Occasionally, they can restrict normal movement of adjacent soft tissues. The color can

Downloaded for Anonymous User (n/a) at Egyptian Knowledge Bank from ClinicalKey.com by Elsevier on March 10, 2024. For personal use only. No other uses without permission. Copyright ©2024. Elsevier Inc. All rights reserved.

vary from pink–purple (early lesions) to skin-colored to hypo- or hyperpigmented. While keloids may be more elevated above the skin surface than hypertrophic scars, the key difference is that keloids extend beyond the boundary of the original wound into adjacent normal skin, often with claw-like extensions resembling the pincers of a crab (in Greek, chelè means claw) (Figs. 98.1 & 98.2). In contrast, hypertrophic scars remain confined to the site of the original injury (Fig. 98.3).

Hypertrophic scars usually develop within a few weeks to months after wounding, and they may flatten spontaneously within 1 to 2 years. Most keloids appear within one year of an injury, although the intervening interval may be up to two decades[5]. Of note, keloids do not regress over time. Both hypertrophic scars and keloids favor sites of increased wound tension such as the upper trunk, shoulder, and upper outer arm. However, keloids can also develop in sites such as the earlobe, where there is minimal tension. In addition, keloids can form spontaneously, most often in the midchest region but there is the possibility of unrecognized skin disease (e.g. acne).

CLINICAL FEATURES OF CONVENTIONAL SCARS, HYPERTROPHIC SCARS, AND KELOIDS			
	Conventional scar	**Hypertrophic scar**	**Keloid**
Preceded by injury	Yes	Yes	Not always
Onset	Within weeks	Few weeks to months	Delayed
Erythema	Temporary	Prominent	Varies
Profile	Flat	Raised	Raised
Symptomatic	No	Yes	Yes
Confined to wound margin	Yes	Yes	No
Spontaneous resolution	N/A	Possible, gradual	Rare
Treatment response	N/A	Good	Poor

Table 98.1 Clinical features of conventional scars, hypertrophic scars, and keloids. N/A, not applicable.

Scar assessment

Scar evaluation ranges from simple scales to technologically advanced devices (e.g. optical coherence tomography) that analyze one or more variables in a reproducible manner[14]. The Vancouver Scar Scale (Table 98.2) and the Patient & Observer Scar Assessment Scale (POSAS) are the most commonly employed assessment tools[14,15]. These scales have significant inter-patient variation because they score subjective features from color to degree of pain and pruritus. More recently, the Japan Scar Workshop (JSW) published the JSW Scar Scale (JSS), a simple and easy tool for objectively diagnosing keloids and hypertrophic scars

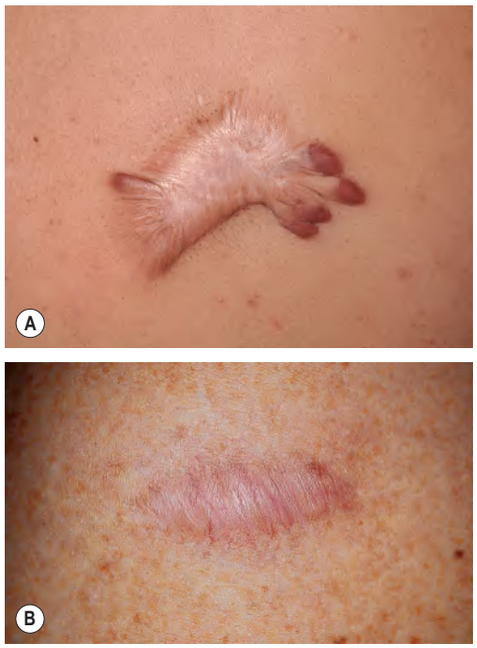

Fig. 98.2 Comparison of a keloid and a hypertrophic scar. A The keloid has claw-like extensions that extend beyond the original wound margin into adjacent normal skin. **B** The hypertrophic scar remains confined to the site of the original surgical wound. *A, Courtesy Edward Cowen, MD; B, Courtesy Jean L. Bolognia, MD.*

Fig. 98.1 Keloids. Common sites include the upper trunk (**A–C**), neck (**D**), and shoulder (**E**). There is a higher prevalence of keloids in patients with darkly pigmented skin, but they can occur in individuals with any skin phototype. Note the extension of the keloids into the normal surrounding skin in a claw-like manner. *C, Courtesy Lorenzo Cerrroni, MD; E, Courtesy Julie V. Schaffer, MD.*

Downloaded for Anonymous User (n/a) at Egyptian Knowledge Bank from ClinicalKey.com by Elsevier on March 10, 2024. For personal use only. No other uses without permission. Copyright ©2024. Elsevier Inc. All rights reserved.

based on risk factors of individual patients and sites of involvement[16]. Non-invasive techniques can also be used to more objectively measure scar color, blood flow, transcutaneous oxygen tension, skin hardness, elasticity, and hydration[17].

Pathology

Distinguishing between a keloid and a hypertrophic scar is important when contemplating treatment, especially more aggressive therapies such as radiation. In some patients, histologic examination is required to make this distinction (Table 98.3). Hypertrophic scars are characterized by an increase in the number of fibroblasts and the density of collagen fibers within the dermis, both of which are oriented parallel to the skin surface. This is accompanied by multiple vertically oriented dermal blood vessels (Fig. 98.4). In keloids, there are whorls and nodules of strikingly thick, glassy, homogeneous collagen bundles that are composed of densely packed fibrils and are oriented haphazardly throughout the dermis (keloidal collagen) (Fig. 98.5). Early on, there are abundant deposits of fibrillary collagen within the reticular dermis of keloids, while mature lesions often have the characteristic thick sclerotic collagen. In longstanding keloids, there may be a return to the earlier fibrillary pattern.

It is noteworthy that keloidal collagen may be absent in up to 45% of keloids[18]. In scars with no detectable keloidal collagen, histologic features that favor a keloid include: no flattening of the epidermis; a lack of fibrosis within the papillary dermis; a tongue-like advancing edge as the scar tissue extends through the reticular dermis; a horizontal cellular fibrous band within the upper reticular dermis with a sharp demarcation from the normal-appearing papillary and reticular dermis; and prominent fascia-like fibrous bands in the deeper portion of the scar[18].

Attempts to differentiate hypertrophic scars from keloids via immunohistochemistry has led to conflicting results[18,19]. In one study, nodules of α-smooth muscle actin (α-SMA)-positive cells (myofibroblasts) were only observed in hypertrophic scars, whereas another investigation found α-SMA expression in both hypertrophic scars (70%) and keloids (45%)[18]. Expression of cyclooxygenase (COX)-1 was observed in 100% of keloids, but it was also expressed in ~50% of hypertrophic scars[19]; thus COX-1 expression favored, but did not specifically identify, keloids. Lastly, *in vitro* differences in fibroblast phenotype, production of extracellular matrix, and CCL5 secretion have been observed[18].

Fig. 98.3 Hypertrophic scar at the site of a knife injury.

Differential Diagnosis

The clinical differential diagnosis of keloids includes the sclerotic form of xanthoma disseminatum, lobomycosis (keloidal blastomycosis; lacaziosis), and the keloidal forms of scleroderma and morphea. Rarely, carcinoma en cuirasse can present as keloidal nodules. Patients with the vascular type of Ehlers–Danlos syndrome may occasionally develop keloidal plaques on their lower extremities, and spontaneous formation of keloids can be a clinical clue to other rare inherited syndromes such as Bethlem myopathy, Rubenstein–Taybi syndrome, and Goeminne syndrome (see above).

Histologically, keloids and hypertrophic scars need to be differentiated from spindle cell tumors, primarily dermatofibroma (DF)[20], dermatofibrosarcoma protuberans (DFSP), dermal fibromatoses, desmoplastic melanoma, and the scar-like variant of squamous cell carcinoma (SCC). Immunostaining for CD34 and factor XIIIa, which is usually positive in DFSP and DF, respectively, is negative in keloids and hypertrophic scars[21]. While there is minimal or no immunostaining for S100 protein in scars, desmoplastic melanomas usually demonstrate strong expression of this marker[22]. Finally, the unusual scar-like variant of SCC may only have focal keratin expression, and a complete panel of keratin stains (to increase sensitivity) may be required for its detection[23].

Treatment

The management of keloids and hypertrophic scars continues to challenge clinicians, and there is no universally accepted treatment algorithm. Potential evidence-based treatments are outlined in Table 98.4[24-33]. Prevention remains the best strategy in predisposed patients, including avoidance of nonessential surgery in high-risk anatomic sites and attention to postsurgical wound care[24]. International guidelines recommend use of silicone gels and sheets in the treatment of both hypertrophic scars and keloids[28]. While potent topical corticosteroids

HISTOPATHOLOGIC FEATURES OF HYPERTROPHIC SCARS AND KELOIDS		
	Hypertrophic scar	**Keloid**
Epidermis	Flattened	Not involved
Papillary dermis	Fibrotic	Not involved
Fibroblasts	Increased	Not increased within keloidal collagen
Collagen bundles	Fine, wavy; orientation is parallel to the epidermis	Large, thick, closely packed; orientation is random relative to the epidermis
Elastic fibers	Diminished or absent	Increased within the deep dermis
Dermal blood vessels	Increased; oriented vertically, perpendicular to the epidermis	Not increased; few, if any, vertically oriented vessels
Inflammatory infiltrate	Sparse, perivascular	Sparse, perivascular
Mast cells	Increased	Increased
Dermal mucin	Increased	Increased
Myofibroblasts	+++	++

Table 98.3 Histopathologic features of hypertrophic scars and keloids. Shading indicates differences.

VANCOUVER SCAR SCALE						
Score for each clinical feature	**0**	**1**	**2**	**3**	**4**	**5**
Pliability	Normal	Supple	Yielding	Firm, solid unit	Banding/"ropes"	Contracture
Height	Flat	<2 mm	2–5 mm	>5 mm	–	–
Vascularity	Normal	Pink	Red	Purple	–	–
Pigmentation	Normal	Hypopigmentation	Hyperpigmentation	–	–	–

Table 98.2 Vancouver Scar Scale. *Adapted from Sullivan T, Smith J, Kermode J, et al. Rating the burn scar. J Burn Care Rehabil 1990;11:256–60.*

Downloaded for Anonymous User (n/a) at Egyptian Knowledge Bank from ClinicalKey.com by Elsevier on March 10, 2024. For personal use only. No other uses without permission. Copyright ©2024. Elsevier Inc. All rights reserved.

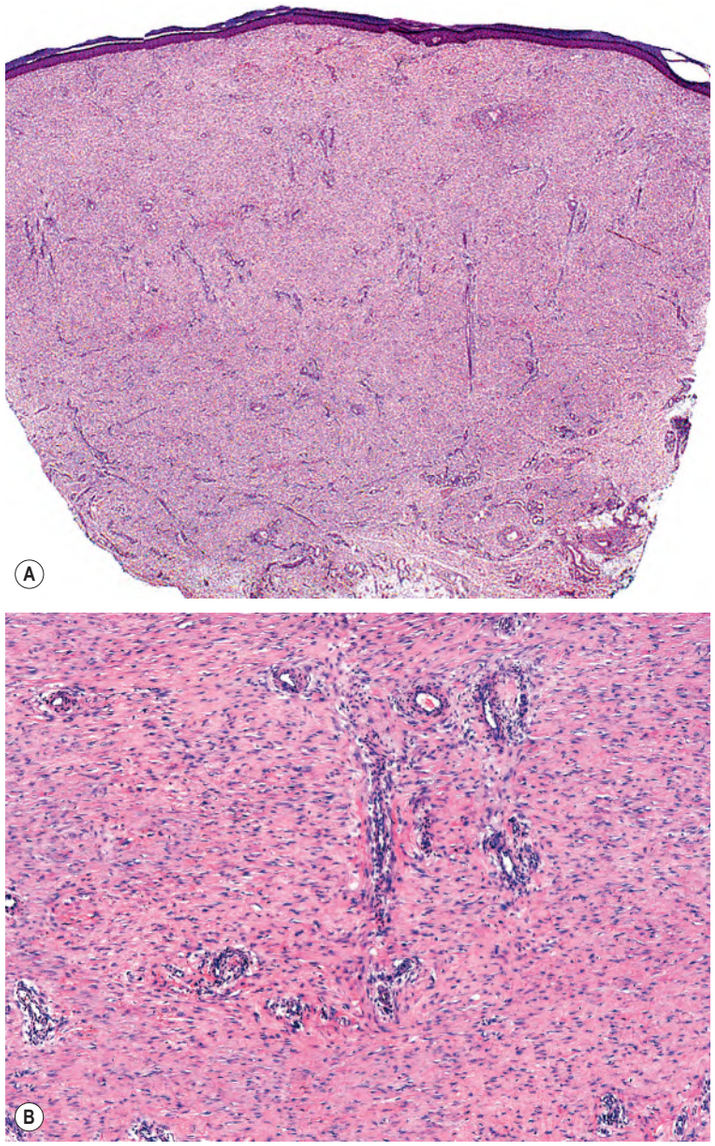

Fig. 98.4 Hypertrophic scar – histopathologic features. A Increased density of collagen fibers within the dermis and vertically oriented blood vessels. **B** Increase in the number of fibroblasts and density of collagen fibers, both of which are oriented horizontally (parallel to the epidermis). The central blood vessel is oriented vertically and there is a sparse perivascular inflammatory infiltrate.

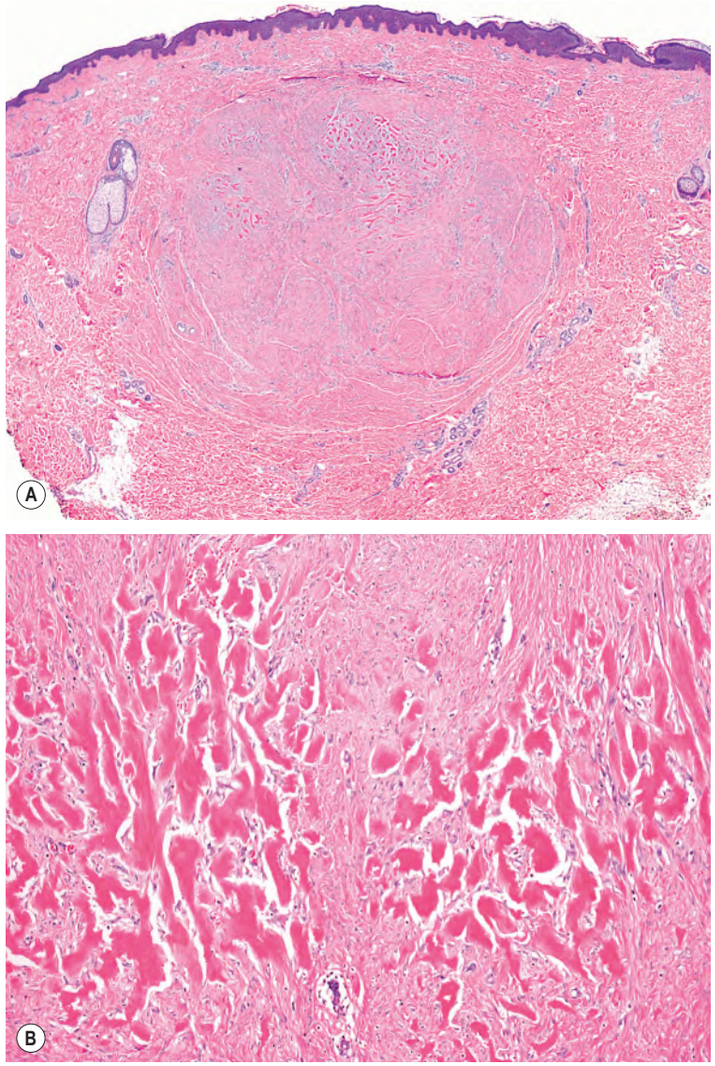

Fig. 98.5 Keloid – histopathologic features. A Nodules of thick collagen bundles are oriented haphazardly within the dermis (keloidal collagen). There is neither flattening of the epidermis nor involvement of the papillary dermis, and a sharp demarcation is seen between the normal-appearing papillary and reticular dermis and the nodules. **B** Strikingly thick, glassy, homogeneous collagen bundles composed of multiple, densely packed fibrils.

are sometimes used to address pruritus, intralesional triamcinolone remains a commonly employed first-line therapy[34]. Incremental increases in triamcinolone concentration may be used to balance flattening effects against the risk of atrophy[29]. An alternative, especially for needle-averse individuals, is clobetasol propionate 0.05% cream under silicone dressing occlusion[30].

Intralesional or topical corticosteroids may be combined with intralesional 5-fluorouracil[31]. For hypertrophic scars and keloids in patients with darker skin color who are at risk for steroid-induced hypopigmentation, intralesional bleomycin and intralesional triamcinolone have been shown to lead to comparable improvement[32]. By reducing muscle tension during wound healing, intralesional botulinum toxin type A can minimize scar formation and reduce associated symptoms[33]; possible explanations include pausing of the fibroblast cell cycle and changes in TGF-β1 expression. Based upon case reports, dupilumab can reduce associated pruritus and may lead to an improvement in appearance[34a].

Surgical revision of hypertrophic scars and keloids can quickly relieve symptoms, but the recurrence rate is quite high. Cryosurgery has been used successfully[24] and is often combined with intralesional triamcinolone. Shave excision followed by contact cryosurgery has also been employed. Pulsed dye laser therapy has become popular as a modality for postsurgical scar reduction and is associated with few side effects. The use of lower cumulative doses has improved the safety of adjuvant postoperative radiation therapy while still maintaining efficacy[25,26] (see Table 98.4 & Ch. 139).

DUPUYTREN DISEASE

Synonyms: ▪ Dupuytren's contracture ▪ Palmar fibromatosis ▪ Dupuytren's diathesis

Key features

- Thickening of palmar and digital fascia
- Progressive flexion contracture of affected digits
- Myofibroblast proliferation followed by excess collagen synthesis
- Treatment includes injections of collagenase, percutaneous needle fasciotomy, and surgical fasciotomy/fasciectomy

History

Henry Cline described thickening of the palmar fascia in 1777 and proposed palmar fasciotomy as a cure. In 1831, Guillaume Dupuytren characterized and popularized this entity.

Downloaded for Anonymous User (n/a) at Egyptian Knowledge Bank from ClinicalKey.com by Elsevier on March 10, 2024. For personal use only. No other uses without permission. Copyright ©2024. Elsevier Inc. All rights reserved.

TREATMENT OPTIONS FOR HYPERTROPHIC SCARS AND KELOIDS		
Treatment	**Mechanism(s) of action**	**Level of evidence**
Silicone sheeting	Reduction in collagen deposition due to an increase in temperature, hydration (reduces water vapor loss), and perhaps oxygen tension	2
Pressure therapy	Pressure-induced hypoxic effects lead to collagen and fibroblast degeneration	2
Onion extract (topical)	Decrease in inflammation and fibroblast proliferation rate	1
Vitamin E (topical)	Antioxidant properties	2
Triamcinolone (intralesional; 10–40 mg/ml)*	Inhibits fibroblast proliferation and collagen synthesis; vasoconstriction; decreases in TGF-β1 and TGF-β2	1
5-Fluorouracil (intralesional; 50 mg/ml not to exceed 100 mg/session; administered weekly)	Inhibits fibroblast proliferation	2
Bleomycin (1.5 IU/ml – multiple puncture technique; maximum 2 ml/cm^2 and 10 IU per session; once monthly)	Direct or indirect, TGF-β-mediated, inhibitory effects on collagen	2
Botulinum toxin (intralesional)	Reduces muscle tension during wound healing, leading to reduction in symptoms, volume and vascularity, presumably due to pausing of the fibroblast cell cycle and changes in TGF-β1 expression	1
Surgical scar revision	Reorientation and construction of multiple tension vectors	2
Cryosurgery (contact and needles more effective than spray; monthly × 3–10 months)*	Direct cellular freezing effects; post-thaw vascular stasis	2
Radiation therapy (postoperative [usually within 72 hours]; 8–10 Gy in a single dose; 6–15 Gy in 3–5 fractions)	Induction of fibroblast apoptosis; restoration of balance between synthesis and degradation of collagen within scar; damage to connective tissue stem cells	2
Laser therapy (pulsed dye laser [PDL] – can begin day of suture removal then every 3–4 weeks; CO_2 fractional laser*; Nd:YAG [1064 nm])	Induces wound contraction and collagen remodeling following thermal necrosis; decreased levels of TGF-β from heat shock response	1 (PDL)
Avotermin (intralesional)†	Recombinant TGF-β3 (form of TGF associated with a reduction in scarring)	1 (phase II trial; no difference in phase III trial)
Human recombinant interleukin-10 (intralesional)†	Anti-inflammatory activity	1‡,¶
Mannose-6-phosphate (intralesional)†	Inhibition of TGF-β1 and TGF-β2 signaling (two forms of TGF associated with an increase in scarring)	1‡
Insulin (intralesional)	Inhibitor of myofibroblasts	1

*Cryotherapy or CO_2 laser sometimes administered prior to intralesional injections of corticosteroids.
†Not commercially available.
‡Based upon phase II trial.
¶In lightly, but not darkly, pigmented individuals.

Table 98.4 Treatment options for hypertrophic scars and keloids. There are also reports of the use of topical retinoic acid, calcineurin inhibitors, imiquimod (deemed ineffective in controlled trials), and tamoxifen; mitomycin C (topical or intralesional); and systemic methotrexate, dupilumab, and calcium channel blockers[75]. Treatments reserved for the treatment of keloids are shaded mid-blue and experimental treatments are shaded dark blue. Key to evidence-based support: (1) prospective controlled trial; (2) retrospective study or large case series; (3) small case series or individual case reports. TGF, transforming growth factor. *Adapted from Tziotzios C, et al. J Am Acad Dermatol 2012;66:13–24.*

Epidemiology

Dupuytren disease is common in White people of northern European ancestry, with a prevalence in Western countries that ranges from 1%–30%; it is rarer in patients with darker skin phototypes. The incidence of Dupuytren disease increases with age and it is most common in middle-aged and older men. Familial associations suggest an autosomal dominant inheritance, but sporadic cases are common. The lesion is associated with other fibromatoses (e.g. plantar fibromatosis, polyfibromatosis; see Ch. 116) as well as diabetes mellitus, liver disease including alcoholic cirrhosis[35], and perhaps epilepsy[35], manual labor[36,37], and cigarette smoking.

Vemurafenib has been linked to new-onset or worsening of Dupuytren disease and plantar fascial fibromatosis. To date, there has been one report of the association of topical timolol with the development of Dupuytren disease and penile fibromatosis[38].

Pathogenesis

Fibrogenic cytokines (e.g. TGF-β1, TGF-β2) are thought to play a role due to their ability to induce collagen production, proliferation of fibroblasts, and the differentiation of fibroblasts into myofibroblasts. Production of tumor necrosis factor (TNF) by M2 macrophages and mast cells in early-stage Dupuytren disease is also thought to activate myofibroblasts, leading to and/or sustaining fibrosis[39]. In genome-wide assays of fibroblasts from Dupuytren disease, the differential expression patterns included genes that encode proteins involved in the extracellular matrix (e.g. collagen), fibrosis (e.g. follistatin), tissue remodeling (e.g. collagenases, matrix metalloproteinases), cellular movement (e.g. kinesins), and signaling pathways (e.g. STAT1, Wnt2), as well as growth factors (e.g. fibroblast growth factor 9)[40]. Activation of the Wnt signaling pathway appears to play a key role as it does in scar formation (see above)[41].

Clinical Features

Patients often present late in the course of their disease with flexion contractures of the affected digits. Lesions usually have an ulnar distribution, and the ring finger is most commonly affected (Fig. 98.6). The disorder begins with a nodule in the fascia of the palm, which grows to produce a cord which then contracts, producing a flexion contracture of the metacarpophalangeal and proximal interphalangeal joints. Complications of Dupuytren disease include nerve injury, loss of joint mobility, and development of complex regional pain syndrome (also referred to as reflex sympathetic dystrophy)[42].

Downloaded for Anonymous User (n/a) at Egyptian Knowledge Bank from ClinicalKey.com by Elsevier on March 10, 2024. For personal use only. No other uses without permission. Copyright ©2024. Elsevier Inc. All rights reserved.

Fig. 98.6 Dupuytren disease. Fibrotic nodule at the base of the fourth finger with an obvious cord extending proximally. In addition to palpation, fibrotic cords can be accentuated by extension of the digit. Eventually, flexion contractures develop.

Pathology

Histologically, the nodular lesion consists of a proliferation of myofibroblasts, which align along lines of tension. The initial stages are more cellular and there are some mitotic figures; the cells may express α-SMA, indicative of myofibroblastic differentiation. Thicker collagen, fewer myofibroblasts, and scarce to absent mitotic figures characterize later stages[43].

Differential Diagnosis

Although usually the diagnosis is straightforward, one must consider a ganglion cyst, giant cell tumor of the tendon sheath, soft tissue sarcoma (e.g. epithelioid sarcoma), callus, and tenosynovitis. An ultrasonographic hypoechoic mass superficial to a flexor tendon of the third, fourth, or fifth digits at the level of the distal metacarpal, where the length of the lesion is greater than its width, is typical for palmar fibromatosis and helps to exclude other diagnoses[44].

A rare case of lung cancer metastasis simulating Dupuytren disease has been reported[45], and in injection drug users, flexion digital contractures (camptodactyly) due to repeated vascular injury and infection of the digits may mimic Dupuytren disease. Flexion contractures of the hand, along with multiple tender nodules, can develop in the rare paraneoplastic palmar fasciitis and polyarthritis syndrome.

Treatment

Although surgical fasciotomy/fasciectomy to release the joint contracture is the mainstay of treatment, minimally invasive procedures such as percutaneous needle fasciotomy and enzymatic fasciotomy with injectable collagenase (from *Clostridium histolyticum*) are increasingly utilized despite higher recurrence rates[46–51]. Patients receive up to three monthly injections of collagenase per cord, followed by passive finger extension 1–3 days later. Complications include bruising, tendon rupture, ligament or nerve injury, and anaphylaxis. Although some authors have advocated the use of radiotherapy during the early stage of Dupuytren disease, a systematic review found limited evidence to support this approach[52].

A risk score determined by whole genome sequencing may predict postsurgical recurrence[53], while ultrasound findings (e.g. mixed echogenicity, nodular structure) may predict recurrence after minimally invasive treatments[54]. Additional possible treatments include intralesional triamcinolone[55], blue light irradiation (to prevent relapse)[56], correction of vitamin D deficiency[57], and use of inhibitors of TGF-β1[58,59], TGF-β2, TNF[60] and one of its receptors TNFR2, or IL-33[39]. New enzymatic approaches are also in development[61].

Fig. 98.7 Cutis verticis gyrata. Cerebriform folding of the skin of the scalp.

CUTIS VERTICIS GYRATA

Key features

- Hypertrophy and folding of the scalp
- Primary (idiopathic) form occurs almost exclusively in males, with an onset at puberty and without facial involvement
- Underlying disorders in the secondary form include endocrinopathies (e.g. acromegaly, myxedema) and genetic disorders (e.g. Turner syndrome)

Clinical Features

Primary cutis verticis gyrata (CVG) consists of overgrowth of the scalp that progresses to produce symmetric gyrate or cerebriform folding of the skin (Fig. 98.7). The folds are usually aligned in an anterior–posterior direction on the crown and vertex and are soft to spongy on palpation. Typically, terminal hair density is reduced on the folds, but not in the furrows. Primary CVG can be subdivided into: (1) isolated CVG; and (2) CVG associated with neurologic and/or ophthalmologic abnormalities. Both subtypes have a male predominance and usually develop around puberty. Secondary CVG is less common and its onset varies from birth to adulthood. In secondary CVG, there is a more equal sex distribution and it may be asymmetric, depending on the underlying etiology (Table 98.5).

Pathology

Biopsy specimens typically show normal skin or diffuse dermal thickening with packed hyalinized collagen and an increased number of fibroblasts. Prominent adnexal structures may be present.

Differential Diagnosis

A cerebriform congenital melanocytic nevus of the scalp may simulate CVG. One must also differentiate the latter from pachydermoperiostosis (primary hypertrophic osteoarthropathy), which is associated with facial involvement, thickening of the skin on the hands and feet, and clubbing of the digits. Patients with pachydermoperiostosis have underlying homozygous or compound heterozygous mutations in *SLCO2A1* or *HPGD*, which encode a prostaglandin transporter and 15-hydroxyprostaglandin dehydrogenase, respectively. Pachydermia is observed in both groups, but exaggerated CVG-like skin changes are associated with mutations in *SLCO2A1* (Fig. 98.8)[62].

Furrowed skin on the scalp, forehead, preauricular areas, neck, trunk, palms, and soles in association with acanthosis nigricans, craniosynostosis, and a prominent umbilical stump characterizes Beare–Stevenson

Downloaded for Anonymous User (n/a) at Egyptian Knowledge Bank from ClinicalKey.com by Elsevier on March 10, 2024. For personal use only. No other uses without permission. Copyright ©2024. Elsevier Inc. All rights reserved.

CUTIS VERTICIS GYRATA – DISEASE ASSOCIATIONS
Primary isolated
• None
Primary with associated anomalies
• Neurologic (e.g. intellectual disability, seizures) • Ophthalmologic (e.g. cataracts, optic atrophy)
Secondary
• Acromegaly, pseudoacromegaly • Myxedema (including cretinism)* • Insulin resistance† and HIV-related lipodystrophy with insulin resistance[76] • Graves disease* • Turner and Noonan syndromes (following resolution of intrauterine lymphedema)* • Fragile X syndrome • Klinefelter syndrome • Hereditary neuralgic amyotrophy • Tuberous sclerosis complex • Hyper-IgE syndrome, autosomal dominant • Rosenthal–Kloepfer syndrome (acromegaloid changes, corneal leukoma) • Vemurafenib (selective BRAF inhibitor) + radiotherapy‡[77] • Paraneoplastic due to metastatic carcinoma
*Increased dermal mucin may also be observed. †May also have acanthosis nigricans. ‡Due to multiple follicular cysts and milia.

Table 98.5 Cutis verticis gyrata – disease associations.

CLINICAL FEATURES OF HYALINE FIBROMATOSIS SYNDROME	
Good prognosis (classic juvenile hyaline fibromatosis)	**Poor prognosis (classic infantile systemic hyalinosis)**
Onset during childhood (<5 years old) and survival into adulthood	Onset during infancy
Firm, pearly papules (favoring the perinasal area and ears)	
Verrucous perianal nodules	
Firm nodules/tumors favoring the scalp, neck, hands, and trunk	Reddish-blue to brown plaques overlying extensor surfaces of joints
	Diffusely thickened skin
Gingival hypertrophy	
Joint contractures	
Osteopenia and osteolytic lesions due to hyaline deposits	
No visceral involvement	Persistent diarrhea
	Recurrent infections
	Visceral involvement
Normal mental development	

Table 98.6 Clinical features of hyaline fibromatosis syndrome.

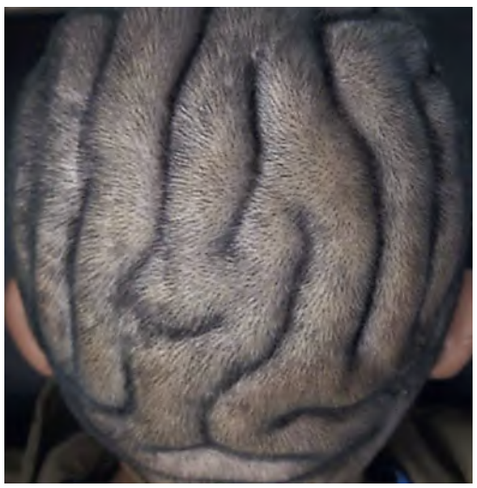

Fig. 98.8 Pachydermoperiostosis (primary hypertrophic osteoarthropathy). There is exaggerated cutis verticis gyrata-like folding of the scalp skin. *Courtesy Dr D. Timaná and Dr J. Valverde, Hospital Docente de Trujillo.*

cutis gyrata syndrome, an autosomal dominant condition caused by mutations in *FGFR2*. Patients with Goeminne syndrome may also have CVG-like folding of the scalp in conjunction with congenital torticollis, multiple keloids, cryptorchidism, and renal dysplasia (TKCR syndrome).

Other potential simulators of CVG include dissecting cellulitis of the scalp, benign hamartomas or tumors (e.g. plexiform neurofibroma, cutaneous neurocristic hamartoma[63], connective tissue nevus, nevus lipomatosus, aggregated cylindromas), primary systemic amyloidosis, leukemia cutis, and malignancies such as folliculotropic mycosis fungoides and angiosarcoma[64]. Based upon patient history, trauma has preceded the development of CVG and there are isolated reports of CVG-like presentations of pemphigus vegetans, Darier disease, scleromyxedema[65], and chronic actinic dermatitis[66] but clinical differentiation is more straightforward.

Treatment

CVG is generally asymptomatic and requires no treatment. Occasionally, surgical excision is performed. Improvement has been reported following injection of hyaluronidase[67].

HYALINE FIBROMATOSIS SYNDROME (JUVENILE HYALINE FIBROMATOSIS AND INFANTILE SYSTEMIC HYALINOSIS)

Synonyms: ▪ Murray–Puretic–Drescher syndrome ▪ Fibromatosis hyalinica multiplex juvenilis ▪ (Juvenile) systemic hyalinosis

Key features

- Rare autosomal recessive disorder with variable phenotypic expression
- Usually presents during infancy or early childhood
- Papulonodules that favor the ears, scalp, neck, hands, and periorificial areas plus gingival hypertrophy and flexion contractures of large joints
- Mutations in the gene that encodes anthrax toxin receptor 2 (*ANTXR2*)
- Treatment consists of excision of nodules and gingivae as needed, but lesions often recur

Introduction

Hyaline fibromatosis syndrome (HFS) is a rare autosomal recessive genodermatosis characterized by hyaline accumulation within the dermis. HFS encompasses both juvenile hyaline fibromatosis (JHF) and infantile systemic hyalinosis (ISH). These two disorders are allelic, i.e. they are due to mutations in the same gene, but differ in severity and visceral involvement[68] (Table 98.6).

History

In 1873, Murray described a condition which he termed "molluscum fibrosum". In 1972, Kitano and colleagues renamed the disorder "juvenile hyaline fibromatosis".

Epidemiology

HFS is a rare disorder that presents during infancy or early childhood.

Downloaded for Anonymous User (n/a) at Egyptian Knowledge Bank from ClinicalKey.com by Elsevier on March 10, 2024. For personal use only. No other uses without permission. Copyright ©2024. Elsevier Inc. All rights reserved.

Fig. 98.9 Juvenile hyaline fibromatosis. Firm pearly papules favor the ears.

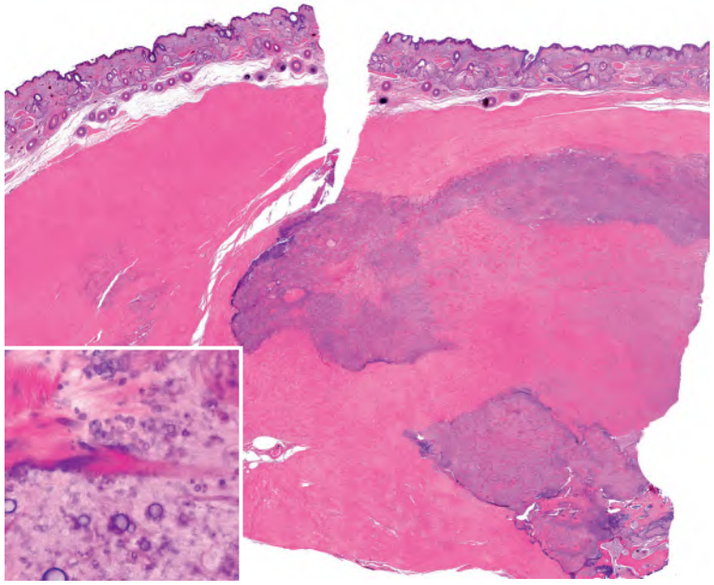

Fig. 98.10 Juvenile hyaline fibromatosis – histopathologic features. Abundant, dense, homogeneous, hyaline (PAS-positive) collagen within the lower dermis and subcutis. Round basophilic calcospherites are also present (inset).

Pathogenesis

Mutations are present in the gene that encodes anthrax toxin receptor 2 (ANTXR2), also referred to as capillary morphogenesis protein-2 (CMG2). ANTXR2 is a transmembrane protein that binds to laminins and types IV and VI collagen (as well as the anthrax toxin). In the skin it is thought to play a role in cell–matrix interactions and basement membrane integrity. Because ANTXR2/CMG2 is thought to target collagen VI for degradation, its dysfunction leads to an accumulation of collagen VI and a subsequent sequestration of inactive matrix metalloproteinases by excess collagen VI, thus leading to fibrosis[69]. As noted previously, mutations in *ANTXR2* can lead to either mild or severe forms of HFS[70]. Missense and other in-frame mutations of the cytoplasmic domain tend to cause a phenotype with a better prognosis (JHF), whereas truncating and missense mutations of the extracellular protein-binding domain lead to a more severe phenotype (ISH). Because ANTXR2 is not expressed in the brain, mental development is not impaired.

Clinical Features

Initially, firm papules and nodules develop on the scalp, ears, neck, and face (particularly perinasal and perioral regions) as well as the perianal area (Fig. 98.9); papulonodules also favor the hands. Patients often suffer severe physical limitations from joint contractures and tumors. Additional clinical features are outlined in Table 98.6. Milder phenotype and later onset has been observed in females[71].

Pathology

Ill-defined nodules composed of dense, homogeneous, hyaline (PAS-positive) collagen are seen within the dermis and, in larger lesions, the subcutaneous tissue (Fig. 98.10). Mononuclear cells and $CD68^+$, osteoclast-like giant cells may be present in a perivascular location in addition to perivascular calcification and eosinophilic globules. Over time, the lesions tend to become more paucicellular, and calcospherites or larger areas of calcification are frequently seen (Fig. 98.10, inset).

Differential Diagnosis

HFS needs to be distinguished from the autosomal recessive disorders MONA (multicentric osteolysis, nodulosis, and arthropathy) and Winchester syndrome which are due to mutations in genes that encode matrix metalloproteinases. Both can have joint contractures, coarse facies, thickened skin and gingival hypertrophy, with painful nodules, especially of the soles, in the former. Histologically, both disorders feature a proliferation of fibroblasts and thickened collagen bundles extending from the deep dermis to the hypodermis. Other genodermatoses to consider include Farber lipogranulomatosis, lipoid proteinosis, infantile myofibromatosis, terminal osseous dysplasia, and the rarer diffuse variant of stiff skin syndrome that is due to fibrillin-1 mutations and inherited in an autosomal dominant pattern.

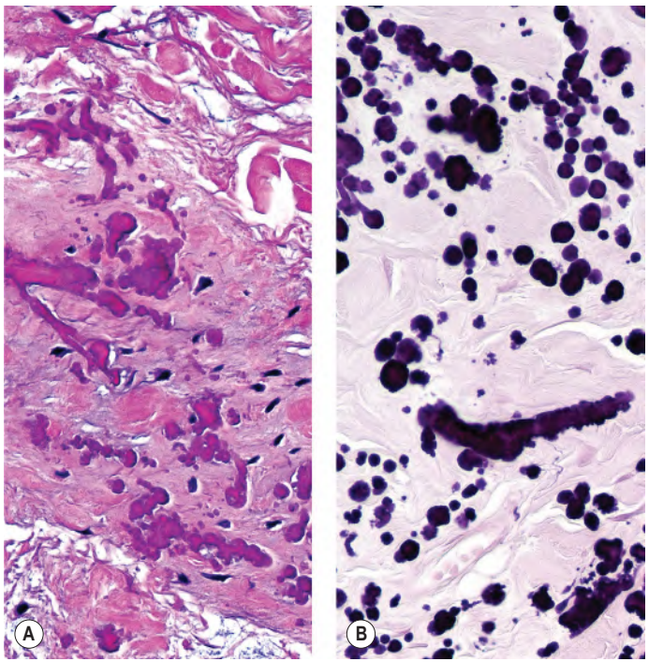

Fig. 98.11 Elastofibroma dorsi – histopathologic features. A Irregular, partially fragmented elastic fibers admixed with swollen collagen bundles. **B** An elastic tissue stain accentuates the fragmented fibers.

Treatment

Treatment options are limited. Surgical excision of nodules and gingival hypertrophy and release of contractures can be performed, but lesions often recur. Diode laser therapy improved skin and mucosal lesions in one patient, but these recurred[72]. Physiotherapy may slow the progression of joint contractures. Injections of corticosteroids into fibromas have met with limited success. Subcutaneous interferon-α-2b therapy improved the skin lesions, gingival hypertrophy, and joint mobility in a patient

Downloaded for Anonymous User (n/a) at Egyptian Knowledge Bank from ClinicalKey.com by Elsevier on March 10, 2024. For personal use only. No other uses without permission. Copyright ©2024. Elsevier Inc. All rights reserved.

DISORDERS CHARACTERIZED BY INCREASED ELASTIC TISSUE FIBERS			
Disorder	**Clinical features**	**Histopathologic features**	**Comments**
Idiopathic or inherited			
Late-onset focal dermal elastosis (focal dermal elastosis)[78]	Multiple 1–3 mm yellow papules that may coalesce Favors the neck and other flexural areas	Increased normal-appearing elastic fibers in the mid and deep reticular dermis	Lacks the systemic features of PXE (see Ch. 97)
Linear focal elastosis (elastotic striae)	Multiple yellow, palpable, striae-like bands Favors the lumbosacral region	Focal increase in number of elongated or fragmented elastic fibers (thickened > thinned) within the mid dermis; the ends of the elastic fibers may be split with a "paintbrush" appearance Early lesions may have inflammation and elastolysis	May represent an excessive regenerative process of elastic fibers, perhaps to repair striae distensae (see Ch. 99)
Elastoderma	Localized areas of lax, pendulous skin with reduced elasticity; neck, trunk, arm	Increased normal- and abnormal-appearing elastic fibers throughout the dermis and subcutis	Lacks the systemic features of PXE (see Ch. 97) Overlaps with cutaneous aging, but earlier onset
Elastofibroma dorsi	Large mass in the deep subcutaneous tissue of the infrascapular area Rarely develops at thoracotomy sites, perhaps related to widened intercostal spaces	Arises within the fascia Increased elastic fibers with a globular and beaded morphology admixed with plump collagen bundles, fibroblasts, and mature fat cells (Fig. 98.11)	Favors older women > men and Japanese Possibly related to chronic mechanical stress Upregulation of TGF-β1 and basic fibroblast growth factor
Elastoma (nevus elasticus)	Firm, skin-colored to yellowish papule(s) which may be clustered Favors the trunk	Accumulation of thick, tortuous, branching elastic fibers within the reticular dermis	Type of connective tissue nevus (see Ch. 116) Associated with Buschke–Ollendorf syndrome (dermatofibrosis lenticularis disseminata)
Elastosis perforans serpiginosa	Annular and polycyclic plaques composed of keratotic papules Favors the neck, face, antecubital fossae, and other flexural areas	Transepidermal or perifollicular channels that contain fragments of elastotic material Increased number of coarse elastic fibers in the superficial dermis No secondary calcium deposition on elastic fibers	Associated with penicillamine (lumpy-bumpy fibers*), Down syndrome and connective tissue disorders (e.g. Ehlers–Danlos syndrome, Marfan syndrome; see Ch. 96)
Pseudoxanthoma elasticum (PXE)	Yellowish skin papules and "cobble-stoned" plaques; redundant folds Favors flexural sites, especially the neck and axillae, and periumbilical region	Distorted and fragmented elastic fibers (elastorrhexis) in mid and deep reticular dermis Calcium deposition on altered elastic fibers	Angioid streaks (Bruch membrane of eye), GI hemorrhage, atherosclerotic cardiovascular disease (see Ch. 97)
Related to cumulative actinic damage (see Fig. 87.24)			
Actinic or solar elastosis (including cutis rhomboidalis nuchae, solar elastotic bands, elastotic nodules of the ear)	Yellow to yellow–white, thickened, coarsely wrinkled skin that favors the lateral forehead, malar region, posterolateral neck, mid extensor arms Bands – forearms Nodules – antihelix > helix	Bluish-grey elastotic material composed of degenerated elastic fibers within the upper and mid dermis In more advanced phases, the elastotic material may aggregate into dense amorphous masses ("actinic elastoma")	Photodamage may be accelerated by medications, e.g. voriconazole (see Ch. 87)
Favré-Racouchot syndrome (nodular elastosis with cysts and comedones)	Bilateral, clustered, open > closed comedones within thickened skin Favors malar prominence and lateral periorbital region	Severe solar elastosis with follicular distention and cystic structures filled with compact keratin	See Ch. 87
Acrokeratoelastoidosis	Bands of waxy or translucent papules and plaques Favors ulnar side of thumb and radial side of forefinger	Shallow depression of the epidermis Usually a decrease in thin and partially fragmented elastic fibers in the mid and deep reticular dermis In some cases, elastic fibers are increased, coarse, and aggregated	May be exacerbated by trauma Also an inherited form that can involve non-sun-exposed sites of the hands and/or feet (see Ch. 58)
Elastoma of Dubreuilh	Yellow to yellow–brown papules or plaques Favor forehead, cheeks, lateral neck	Amorphous masses composed of aggregated elastotic material in the upper dermis	See Ch. 87
*By electron microscopy.			

Table 98.7 Disorders characterized by increased elastic tissue fibers. Special stains for elastic fibers include Verhoeff–van Gieson and orcein (acid orcein–Giemsa; see Ch. 0). GI, gastrointestinal.

with JHF. Based on *in vitro* results, proteasome inhibitors may represent a future therapy for HFS patients with ectodomain-related mutations in *ANTXR2*[73].

ELASTIC TISSUE-RELATED DISORDERS

In general, mechanisms which lead to increased dermal elastic tissue are unknown, and the nosology of the elastic tissue-related disorders can be confusing[74]. There are several acquired disorders whose clinical appearance can overlap. Their clinical and histopathologic features are outlined in Table 98.7.

Additional figures and tables on Differences in adult versus fetal wound healing, Treatment options for Dupytren disease, and Differential diagnosis of hyaline fibromatosis syndrome, available in our eBook (see inside front cover for access code).

Downloaded for Anonymous User (n/a) at Egyptian Knowledge Bank from ClinicalKey.com by Elsevier on March 10, 2024. For personal use only. No other uses without permission. Copyright ©2024. Elsevier Inc. All rights reserved.

REFERENCES

1. Sorg H, Tilkorn DJ, Hager S, et al. Skin wound healing: an update on the current knowledge and concepts. *Eur Surg Res*. 2017;58:81–94.
2. English RS, Shenefelt PD. Keloid and hypertrophic scars. *Dermatol Surg*. 1999;25:631–638.
3. Niessen FB, Spauwen PH, Schalkwijk J, Kon M. On the nature of hypertrophic scars and keloids: a review. *Plast Reconstr Surg*. 1999;104:1435–1458.
4. Alster TS, Tanzi EL. Hypertrophic scars and keloids: etiology and management. *Am J Clin Dermatol*. 2003;4:235–243.
5. Nemeth AJ. Keloids and hypertrophic scars. *J Dermatol Surg Oncol*. 1993;19:738–746.
6. Jfri A, Alajmi A. Spontaneous keloids: a literature review. *Dermatology*. 2018;234:127–130.
7. Profyris C, Tziotzios C, Do Vale I. Cutaneous scarring: pathophysiology, molecular mechanisms, and scar reduction therapeutics Part I. The molecular basis of scar formation. *J Am Acad Dermatol*. 2012;66:1–10.
8. Berman B, Maderal A, Raphael B. Keloids and hypertrophic scars: pathophysiology, classification, and treatment. *Dermatol Surg*. 2017;43(Suppl 1):S3–S18.
9. Cole J, Tsou R, Wallace K, et al. Early gene expression profile of human skin to injury using high-density cDNA microarrays. *Wound Repair Regen*. 2001;9:360–370.
10. Schafer M, Werner S. Transcriptional control of wound repair. *Annu Rev Cell Dev Biol*. 2007;23:69–92.
11. Werner S, Grose R. Regulation of wound healing by growth factors and cytokines. *Physiol Rev*. 2003;83:835–870.
12. Shah M, Foreman DM, Ferguson MW. Neutralisation of TGF-beta 1 and TGF-beta 2 or exogenous addition of TGF-beta 3 to cutaneous rat wounds reduces scarring. *J Cell Sci*. 1995;108:985–1002.
13. Brusselaers N, Pirayesh A, Hoeksema H, et al. Burn scar assessment: a systematic review of different scar scales. *J Surg Res*. 2010;164:e115–e123.
14. Van de Kar A, Corion L, Smeulders M, et al. Reliable and feasible evaluation of linear scars by the patient and observer scar assessment scale. *Plast Reconstr Surg*. 2005;116:514–522.
15. Ogawa R, Akita S, Akaishi S, et al. Diagnosis and treatment of keloids and hypertrophic scars: Japan Scar Workshop consensus document 2018. *Burns Trauma*. 2019;7:39.
16. Nguyen DQ, Potokar T, Price P. A review of current objective and subjective scar assessment tools. *J Wound Care*. 2008;17:101–102. 104–6.
17. Lee JY, Yang CC, Chao SC, Wong TW. Histopathological differential diagnosis of keloid and hypertrophic scar. *Am J Dermatopathol*. 2004;26:379–384.
18. Abdou AG, Maraee AH, Saif HF. Immunohistochemical evaluation of COX-1 and COX-2 expression in keloid and hypertrophic scar. *Am J Dermatopathol*. 2014;36:311–317.
19. Limandjaja GC, Niessen FB, Scheper R, et al. Hypertrophic scars and keloids: overview of the evidence and practical guide for differentiating between these abnormal scars. *Exp Dermatol*. 2021;30:146–161.
20. Kuo T, Hu S, Chan H. Keloidal dermatofibroma: report of 10 cases of a new variant. *Am J Surg Pathol*. 1998;22:564–568.
21. Kaneishi NK, Cockerell CL. Histologic differentiation of desmoplastic melanoma from cicatrices. *Am J Dermatopathol*. 1998;20:128–134.
22. Velázquez EF, Werchniack AE, Granter SR. Desmoplastic/spindle cell squamous cell carcinoma of the skin. A diagnostically challenging tumor mimicking a scar: clinicopathologic and immunohistochemical study of 6 cases. *Am J Dermatopathol*. 2010;32:333–339.
23. Tziotzios C, Profyris C, Sterling J. Cutaneous scarring: pathophysiology, molecular mechanisms, and scar reduction therapeutics Part II. Strategies to reduce scar formation after dermatologic procedures. *J Am Acad Dermatol*. 2012;66:13–24.
24. Ogawa R, Tosa M, Dohi T, et al. Surgical excision and postoperative radiotherapy for keloids. *Scars Burn Heal*. 2019;5:2059513119891113.
25. Son Y, Phillips EON, Price KM, et al. Treatment of keloids with a single dose of low-energy superficial X-ray radiation to prevent recurrence after surgical excision: an *in vitro* and *in vivo* study. *J Am Acad Dermatol*. 2020;83:1304–1314.
26. Bao Y, Xu S, Pan Z, et al. Comparative efficacy and safety of common therapies in keloids and hypertrophic scars: a systematic review and meta-analysis. *Aesth Plast Surg*. 2020;44:207–218.
27. de Oliveira GV, Gold MH. Silicone sheets and new gels to treat hypertrophic scars and keloids: a short review. *Dermatol Ther*. 2020;33:e13705.
28. Luther CA, Griffith JL, Kurland E, et al. The infection rate of intralesional triamcinolone and the safety of compounding in dermatology for intradermal and subcutaneous injection: a retrospective medical record review. *J Am Acad Dermatol*. 2020;83:1044–1048.
29. Nor NM, Ismail R, Jamil A, et al. A randomized, single-blind trial of clobetasol propionate 0.05% cream under silicone dressing occlusion versus intra-lesional triamcinolone for treatment of keloid. *Clin Drug Investig*. 2017;37:295–301.
30. Shah VV, Aldahan AS, Mlacker S, et al. 5-Fluorouracil in the treatment of keloids and hypertrophic scars: a comprehensive review of the literature. *Dermatol Ther (Heidelb)*. 2016;6:169–183.
31. Bik L, Sangers T, Greveling K, et al. Efficacy and tolerability of intralesional bleomycin in dermatology: a systematic review. *J Am Acad Dermatol*. 2020;83:888–903.
32. Sohrabi C, Goutos I. The use of botulinum toxin in keloid scar management: a literature review. *Scars Burn Heal*. 2020;6:2059513120926628.
33. Broekstra DC, Groen H, Molenkamp S, et al. A systematic review and meta-analysis on the strength and consistency of the associations between Dupuytren disease and diabetes mellitus, liver disease, and epilepsy. *Plast Reconstr Surg*. 2018;141:367e–379e.
34. Wong TS, Li JZ, Chen S, et al. The efficacy of triamcinolone acetonide in keloid treatment: a systematic review and meta-analysis. *Front Med (Lausanne)*. 2016;3:71.

34a. Peterson DM, Damsky WE, Vesely MD. Treatment of lichen sclerosus and hypertrophic scars with dupilumab. *JAAD Case Rep*. 2022;23:76–78.

35. Mathieu S, Naughton G, Descatha A, et al. Dupuytren's disease and exposure to vibration: systematic review and meta-analysis. *Joint Bone Spine*. 2020;87:203–207.
36. Fadel M, Leclerc A, Evanoff B, et al. Association between occupational exposure and Dupuytren's contracture using a job-exposure matrix and self-reported exposure in the CONSTANCES cohort. *Occup Environ Med*. 2019;76:845–848.
37. Oliphant H, Gouws P. Peyronie's disease and Dupuytren's contracture secondary to topical timolol. *Int Ophthalmol*. 2019;39:683–685.
38. Izadi D, Layton TB, Williams L, et al. Identification of TNFR2 and IL-33 as therapeutic targets in localized fibrosis. *Sci Adv*. 2019;5:eaay0370.
39. Forrester HB, Temple-Smith P, Ham S, et al. Genome-wide analysis using exon arrays demonstrates an important role for expression of extra-cellular matrix, fibrotic control and tissue remodelling genes in Dupuytren's disease. *PLoS ONE*. 2013;8:e59056.
40. Ng M, Thakkar D, Southam L, et al. A genome-wide association study of Dupuytren disease reveals 17 additional variants implicated in fibrosis. *Am J Hum Genet*. 2017;101:417–427.
41. Weinzweig N, Culver JE, Fleegler EJ. Severe contractures of the proximal interphalangeal joint in Dupuytren's disease: combined fasciectomy with capsuloligamentous release versus fasciectomy alone. *Plast Reconstr Surg*. 1996;97:560–566.
42. Requena L, Kutzner H. Fibromatosis. In: Requena L, Kutzner H, eds. *Cutaneous Soft Tissue Tumors*. Philadelphia: Wolters Kluwer Health; 2015:117–126.
43. Morris G, Jacobson JA, Kalume Brigido M, et al. Ultrasound features of palmar fibromatosis or Dupuytren contracture. *J Ultrasound Med*. 2019;38:387–392.
44. Ragois P, Didailler P, Rizzi P. Métastase cutanée d'un cancer pulmonaire simulant une maladie de Dupuytren. *Chir Main*. 2012;31:259–261.
45. Hurst LC, Badalamente MA, Hentz VR, et al. Injectable collagenase *Clostridium histolyticum* for Dupuytren's contracture CORD I Study Group. *N Engl J Med*. 2009;361:968–979.
46. Werlinrud JC, Hansen KL, Larsen S, Lauritsen J. Five-year results after collagenase treatment of Dupuytren disease. *J Hand Surg Eur Vol*. 2018;43:841–847.
47. Soreide E, Murad MH, Denbeigh JM, et al. Treatment of Dupuytren's contracture: a systematic review. *Bone Joint J*. 2018;100:1138–1145.
48. Scherman P, Jenmalm P, Dahlin LB. Three-year recurrence of Dupuytren's contracture after needle fasciotomy and collagenase injection: a two-centre randomized controlled trial. *J Hand Surg Eur Vol*. 2018;43:836–840.
49. Strömberg J, Ibsen Sörensen A, Fridén J. Percutaneous needle fasciotomy versus collagenase treatment for Dupuytren contracture: a randomized controlled trial with a two-year follow-up. *J Bone Joint Surg Am*. 2018;100:1079–1086.
50. Nordenskjöld J, Lauritzson A, Åkesson A, Atroshi I. Collagenase injections for Dupuytren disease: 3-year treatment outcomes and predictors of recurrence in 89 hands. *Acta Orthop*. 2019;90:517–522.
51. Kadhum M, Smock E, Khan A, Fleming A. Radiotherapy in Dupuytren's disease: a systematic review of the evidence. *J Hand Surg Eur Vol*. 2017;42:689–692.
52. Riesmeijer SA, Manley OWG, Ng M, et al. A weighted genetic risk score predicts surgical recurrence independent of high-risk clinical features in Dupuytren's disease. *Plast Reconstr Surg*. 2019;143:512–518.
53. Vanek P, Strömberg J, Fridén J, Aurell Y. Morphological patterns of the pretendinous cord in Dupuytren's disease: a predictor of clinical outcome? *J Plast Surg Hand Surg*. 2018;52:240–244.
54. Krassovka J, Borgschulze A, Sahlender B, et al. Blue light irradiation and its beneficial effect on Dupuytren's fibroblasts. *PLoS One*. 2019;14:e0209833.
55. Seyhan H, Stromps JP, Demir E, et al. Vitamin D deficiency may stimulate fibroblasts in Dupuytren's disease via mitochondrial increased reactive oxygen species through upregulating transforming growth factor-β1. *Med Hypotheses*. 2018;116:40–41.
56. Zhou C, Zeldin Y, Baratz ME, et al. Investigating the effects of pirfenidone on TGF-β1 stimulated non-SMAD signaling pathways in Dupuytren's disease-derived fibroblasts. *BMC Musculoskelet Disord*. 2019;20:135.
57. Chisholm J, Gareau AJ, Byun S, et al. Effect of compound 21, a selective angiotensin II type 2 receptor agonist, in a murine xenograft model of Dupuytren disease. *Plast Reconstr Surg*. 2017;140:686e–696ee.
58. Nanchahal J, Ball C, Davidson D, et al. Anti-tumour necrosis factor therapy for Dupuytren's disease: a randomised dose response proof of concept phase 2a clinical trial. *EBioMedicine*. 2018;33:282–288.
59. Rubin G, Rinott M, Wolovelsky A, et al. A new bromelain-based enzyme for the release of Dupuytren's contracture: Dupuytren's enzymatic bromelain-based release. *Bone Joint Res*. 2016;5:175–177.
60. Sasaki T, Niizeki H, Shimizu A, et al. Identification of mutations in the prostaglandin transporter gene SLCO2A1 and its phenotype-genotype correlation in Japanese patients with pachydermoperiostosis. *J Dermatol Sci*. 2012;68:36–44.
61. Saha D, Kini UA, Kini H. Cutaneous neurocristic hamartoma presenting as cutis verticis gyrata. *Am J Dermatopathol*. 2014;36:e66–e69.
62. Kim JE, Choi KH, Kang SJ, et al. Angiosarcoma mimicking cutis verticis gyrata. *Clin Exp Dermatol*. 2011;36:806–808.
63. Koregol S, Yatagiri RV, Warad SR, Itagi NR. A rare association of scleromyxedema with cutis verticis gyrata. *Indian Dermatol Online J*. 2016;7:186–189.
64. Bourgaux M, Marcaillou M, Matei I, et al. Man of stone: a case of a chronic actinic dermatitis mimicking a cutis verticis gyrata. *J Eur Acad Dermatol Venereol*. 2020;34:e129–e130.
65. Welborn M, Dallo C, Altmeyer M. Cutis verticis gyrata improved with injected hyaluronidase treatments. *Dermatol Arch*. 2018;3:74–76.
66. El-Kamah GY, Fong K, El–Ruby M, et al. Spectrum of mutations in the ANTXR2 (CMG2) gene in infantile systemic hyalinosis and juvenile hyaline fibrosis. *Br J Dermatol*. 2010;163:213–215.
67. Bürgi J, Kunz B, Abrami L, et al. CMG2/ANTXR2 regulates extracellular collagen VI which accumulates in hyaline fibromatosis syndrome. *Nat Commun*. 2017;8:15861.
68. Hanks S, Adams S, Douglas J, et al. Mutations in the gene encoding capillary morphogenesis protein 2 cause juvenile hyaline fibromatosis and infantile systemic hyalinosis. *Am J Hum Genet*. 2003;73:791–800.
69. Cozma C, Hovakimyan M, Iurașcu MI, et al. Genetic, clinical and biochemical characterization of a large cohort of patients with hyaline fibromatosis syndrome. *Orphanet J Rare Dis*. 2019;14:209.
70. Fekrazad R, Fazilat F, Kalhori KA, et al. Juvenile hyaline fibromatosis management with a diode laser: a rare case report. *J Lasers Med Sci*. 2020;11:104–107.
71. Deuquet J, Lausch E, Guex N, et al. Hyaline fibromatosis syndrome inducing mutations in the ectodomain of anthrax toxin receptor 2 can be rescued by proteasome inhibitors. *EMBO Mol Med*. 2011;3:208–221.
72. Andrés-Ramos I, Alegría-Landa V, Gimeno I, et al. Cutaneous elastic tissue anomalies. *Am J Dermatopathol*. 2019;41:85–117.
73. Viera MH, Amini S, Valins W, Berman B. Innovative therapies in the treatment of keloids and hypertrophic scars. *J Clin Aesthet Dermatol*. 2010;3:20–26.

Downloaded for Anonymous User (n/a) at Egyptian Knowledge Bank from ClinicalKey.com by Elsevier on March 10, 2024. For personal use only. No other uses without permission. Copyright ©2024. Elsevier Inc. All rights reserved.

74. Khanijow K, Unemori P, Leslie KS, et al. Cutis verticis gyrata in men affected by HIV-related lipodystrophy. *Dermatol Res Pract*. 2013;2013:941740.
75. Lang N, Sterzing F, Enk AH, Hassel JC. Cutis verticis gyrata-like skin toxicity during treatment of melanoma patients with the BRAF inhibitor vemurafenib after whole-brain radiotherapy is a consequence of the development of multiple follicular cysts and milia. *Strahlenther Onkol*. 2014;190:1080–1081.
76. Knapp M, Carpenter CE, Shea K, et al. Focal dermal elastosis: a proposed update to the nomenclature. *Am J Dermatopathol*. 2020;42:774–775.
77. Yin CY, Yu HM, Wang JP, et al. Long-term follow-up of Dupuytren disease after injection of triamcinolone acetonide in Chinese patients in Taiwan. *J Hand Surg Eur Vol*. 2017;42:678–682.
78. Lah M, Niranjan T, Srikanth S, et al. A distinct X-linked syndrome involving joint contractures, keloids, large optic cup-to-disc ratio, and renal stones results from a filamin A (*FLNA*) mutation. *Am J Med Genet A*. 2016;170:881–890.

Downloaded for Anonymous User (n/a) at Egyptian Knowledge Bank from ClinicalKey.com by Elsevier on March 10, 2024. For personal use only. No other uses without permission. Copyright ©2024. Elsevier Inc. All rights reserved.

eFig. 98.1 Multiple keloids due to acne vulgaris. The neck is a common location for keloids.

eFig. 98.2 Spontaneous generalized keloids. Extensive spontaneous keloids in an African-American man. *Courtesy Claude Burton, MD*.

eFig. 98.3 Keloid of the flexor arm in an African-American man. Note the extension of the keloid into the normal surrounding skin in a claw-like manner and the central involution. *Courtesy Claude Burton, MD*.

eFig. 98.4 Keloid of the earlobe in an African-American woman. The earlobe, where piercing has been performed for placement of earrings, is a common site for keloid formation. *Courtesy Joyce Rico, MD*.

eFig. 98.5 Nodular morphea on the shoulder mimicking keloids. *Courtesy Julie V. Schaffer, MD*.

Downloaded for Anonymous User (n/a) at Egyptian Knowledge Bank from ClinicalKey.com by Elsevier on March 10, 2024. For personal use only. No other uses without permission. Copyright ©2024. Elsevier Inc. All rights reserved.

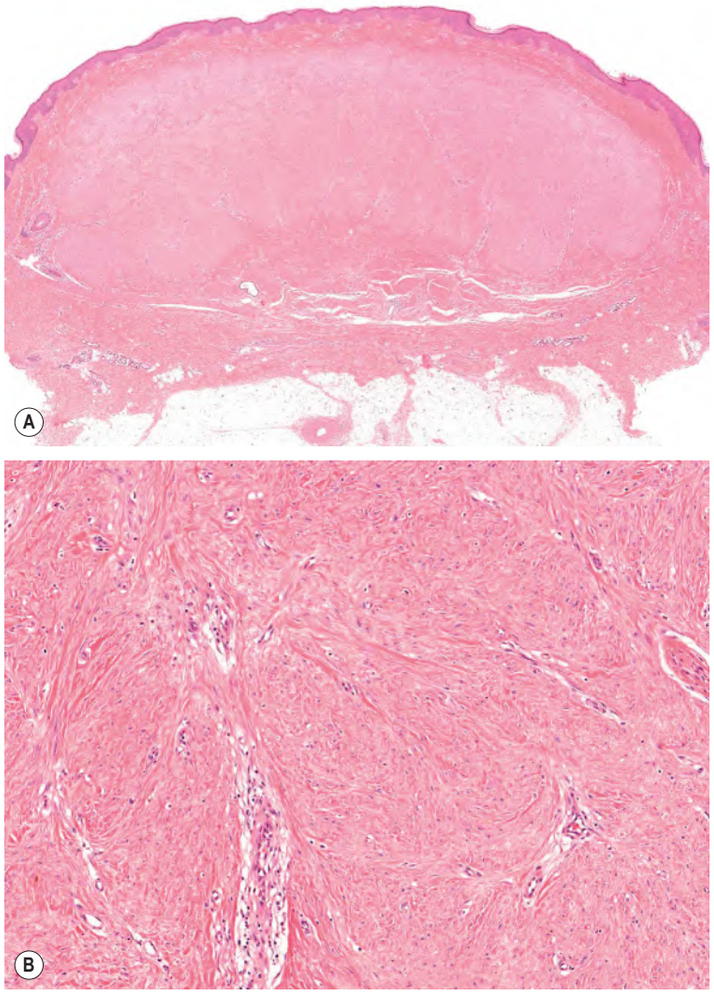

eFig. 98.6 Hypertrophic scar – histopathologic features. A Replacement of the dermis by hypertrophic bundles of collagen with increased numbers of fibroblasts. **B** Vertically oriented blood vessels, nodules of collagen and fibroblasts. *Courtesy Lorenzo Cerrroni, MD*.

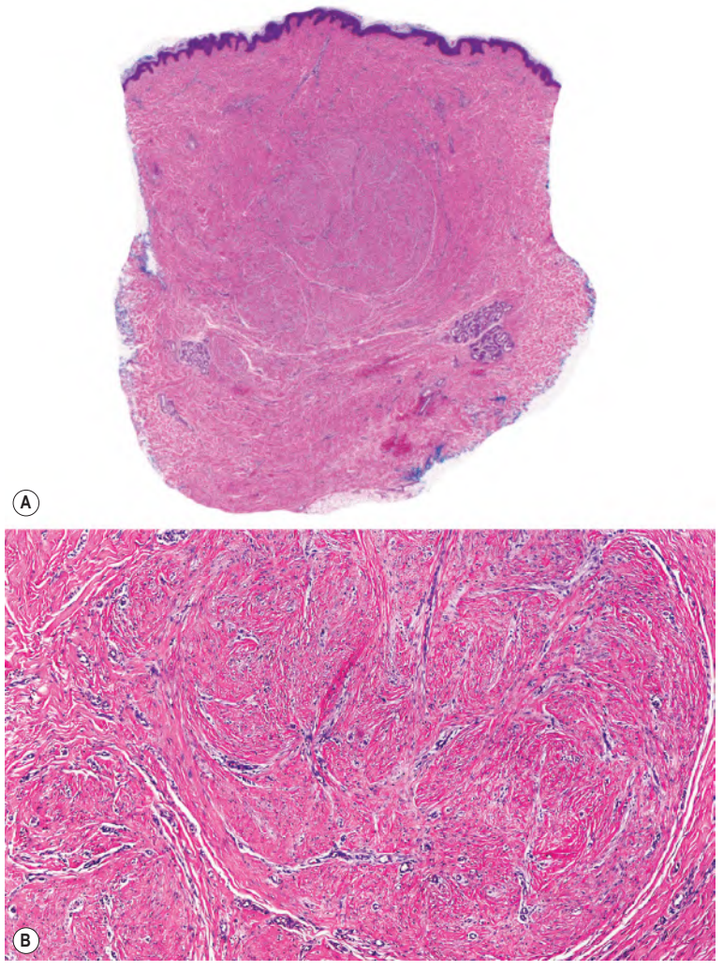

eFig. 98.7 Hypertrophic scar – histopathologic features. A Replacement of the dermis by hypertrophic bundles of collagen with increased numbers of fibroblasts. **B** Nodules of collagen and fibroblasts.

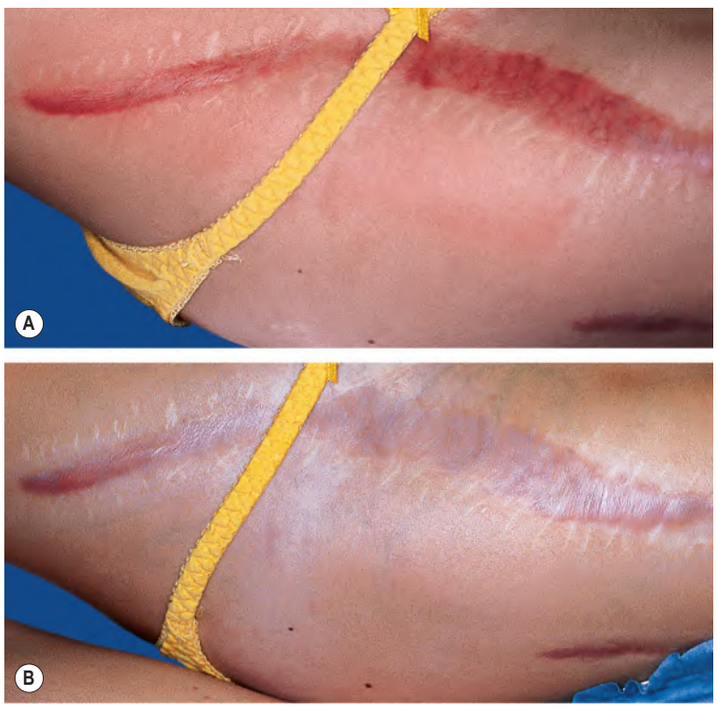

eFig. 98.8 Flashlamp-pumped pulsed dye laser treatment. Hypertrophic scar before (**A**) and after (**B**) treatment with a flashlamp-pumped pulsed dye laser.

eFig. 98.9 Dupuytren disease. There is greater involvement of the fifth finger than the fourth finger. Fibrotic cords can be felt and are accentuated by extension of the digits. Eventually, flexion contractures develop. *Courtesy Jean L. Bolognia, MD*.

Downloaded for Anonymous User (n/a) at Egyptian Knowledge Bank from ClinicalKey.com by Elsevier on March 10, 2024. For personal use only. No other uses without permission. Copyright ©2024. Elsevier Inc. All rights reserved.

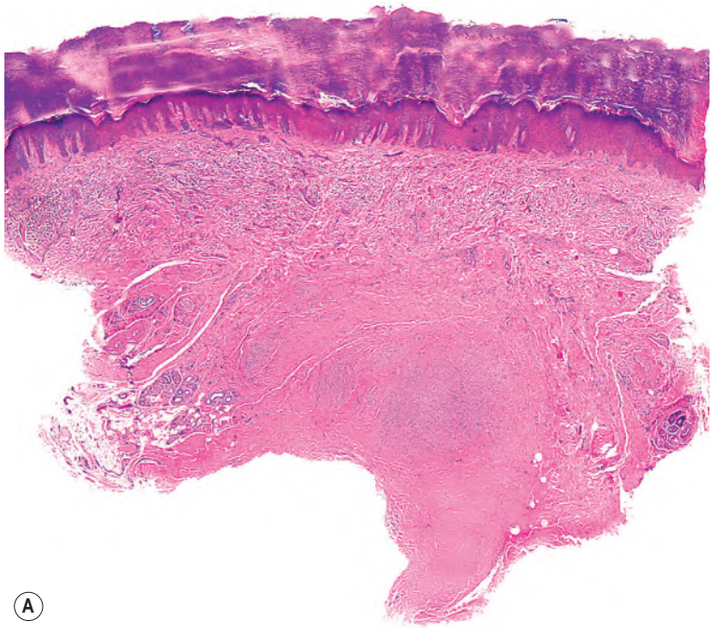

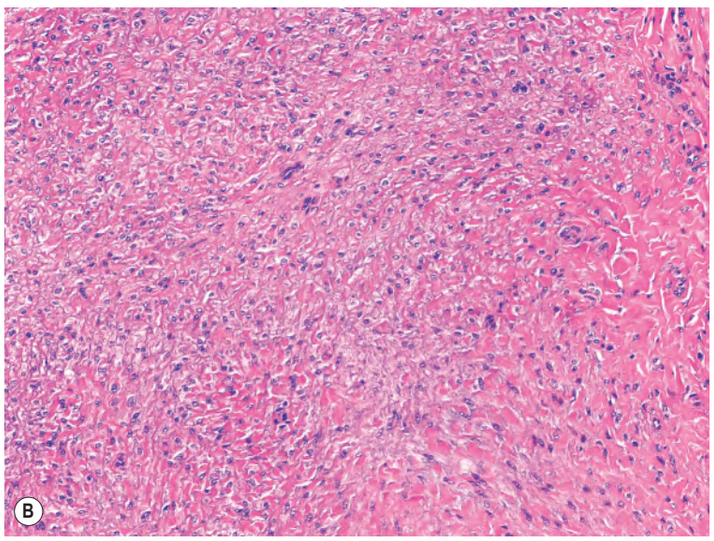

eFig. 98.10 Dupuytren disease – histopathologic features. A Acral skin in which there is a dermal nodule of spindle-shaped cells. **B** Fibroblasts with no mitotic figures embedded in a thick collagen matrix.

eFig. 98.11 Juvenile hyaline fibromatosis. Large subcutaneous nodules are most prominent on the hand, wrist, and elbow. The elbow has an obvious joint contracture.

DIFFERENCES IN ADULT VERSUS FETAL WOUND HEALING		
	Adult	**Fetal**
Fluid environment	No	Yes
Sterile environment	No	Yes
Inflammation	Yes	No
Scar formation	Yes	No
pO_2 (mmHg)	>60	20

eTable 98.1 Differences in adult versus fetal wound healing.

TREATMENT OPTIONS FOR DUPUYTREN DISEASE		
Procedure	**Advantages**	**Disadvantages**
Dermofascie*ctomy* (removes diseased fascia including skin)	Addresses severe disease Lower rate of recurrence	Moderate perioperative morbidity Higher rate of complications* Prolonged rehabilitation High cost
Limited fascie*ctomy* (removes diseased fascia)	Addresses moderate to severe disease Low recurrence rate	Moderate perioperative morbidity Increased risk of scarring Prolonged rehabilitation High cost
Open fascio*tomy* (cord incised; diseased tissue is not excised)	Moderately invasive Good visualization Low complication rate*	Recurrence rate higher than with fasciectomy
Needle fascio*tomy* or percutaneous needle aponeurotomy (PNA) with or without lipofilling (cord fragmented by needle then released by manual force; diseased tissue is not excised)	Minimally invasive Outpatient procedure with local anesthesia Rapid recovery Low cost	Steep learning curve Skin tears Less effective for severe disease High rate of recurrences long-term
Enzymatic fasciotomy with collagenase from *Clostridium histolyticum* (Xiaflex® [USA]; Xiaplex® [Europe])	Minimally invasive Rapid Low risk of complications† First-line therapy or second-line therapy after failure of PNA or fasciectomy	Can only perform on a single cord or two thin cords May require multiple procedures High cost
Intralesional corticosteroids	Minimally invasive Softening of nodules after repeated injections Can improve outcome after PNA Low cost	High recurrence rate – at least 50%

*Complications include digital nerve injury or postoperative neurapraxia, flexor tendon injury/rupture, delayed wound healing or skin necrosis, dysvascular digit/arterial injury, hematoma, infection, and complex regional pain syndrome.
†Complications include bruising, tendon rupture, ligament or nerve injury, and anaphylaxis.

eTable 98.2 Treatment options for Dupuytren disease. *Adapted from Mella JR, Guo L, Hung V. Dupuytren's contracture: an evidence based review. Ann Plast Surg 2018;81(6 S Suppl 1):S97–101.*

Downloaded for Anonymous User (n/a) at Egyptian Knowledge Bank from ClinicalKey.com by Elsevier on March 10, 2024. For personal use only. No other uses without permission. Copyright ©2024. Elsevier Inc. All rights reserved.

DIFFERENTIAL DIAGNOSIS OF HYALINE FIBROMATOSIS SYNDROME			
Disease (mode of inheritance)	**Gene**	**Cutaneous manifestations**	**Extracutaneous manifestations**
MONA (multicentric osteolysis, nodulosis, and arthropathy) (AR)	*MMP2*	Painful nodules on the palms and soles, hypertrichosis, gingival hypertrophy	Osteolysis of hand and foot bones, joint contractures, short stature, corneal opacities, coarse facies
Winchester syndrome	*MMP14*	Thickened hyperpigmented skin, hypertrichosis, gingival hypertrophy	
Farber lipogranulomatosis (AR)	*ASAH1*	Subcutaneous nodules, especially periarticular and at sites of trauma	Arthritis, contractures, progressive hoarseness, variable CNS involvement, hepatosplenomegaly
Lipoid proteinosis (AR) (see Ch. 48)	*ECM1*	Vesicles and hemorrhagic crusts followed by pitted scars, yellow papules and nodules favor the face, verrucous lesions on extensor surfaces	Hoarseness, infiltrated tongue with restricted motion, parotitis, loss of teeth, learning difficulties, seizures
Stiff skin syndrome (AD) (see Ch. 43)	*FBN1*	Induration and thickening of the skin – most often of the buttocks and thighs but more widespread than regional/segmental form, hypertrichosis of affected areas	Restricted joint mobility including hip contractures, short stature, internal organs spared
Mucolipidosis II (AR)	*GNPTAB*	Thickened waxy skin especially around the earlobes, gingival hypertrophy, dermal melanocytosis	Short stature, dysostosis multiplex, skeletal abnormalities, cardiac valve disease, developmental delay, coarse facies
Infantile myofibromatosis (see Ch. 116)	*PDGFRB*	Skin-colored to purple nodules – favor the head and neck region and trunk	Lytic metaphyseal lesions, internal organ involvement, e.g. GI tract, kidneys, lung, heart

eTable 98.3 Differential diagnosis of hyaline fibromatosis syndrome. CNS, central nervous system; GI, gastrointestinal.

Downloaded for Anonymous User (n/a) at Egyptian Knowledge Bank from ClinicalKey.com by Elsevier on March 10, 2024. For personal use only. No other uses without permission. Copyright ©2024. Elsevier Inc. All rights reserved.